

Cytology: The General Principles

Advantages:

The procedure is quick, easy, inexpensive and is a low risk procedure.

Disadvantages:

It provides only limited information with regard to malignancy and spread (see histopathological criteria of spread).

The lesion may contain areas of neoplasia and inflammation and sample may be unrepresentative.

It provides no information with regard to micro-architectural changes.

Experience required in interpretation which is only gained by practice.

Uses:

It can be performed in the clinic, possibly while the client waits.

It may differentiate neoplastic from an inflammatory process.

The results may direct therapy while awaiting other results (esp. histopathology) or suggest the next diagnostic step.

Collection of samples:

Technique depends upon gross appearance, location, likely diagnosis and probable treatment.

- **Impression smears:**

Used for the collection of:

i) Surface material - this is easy and requires only minimal restraint but ulcerated neoplasms (e.g. epitheliotropic lymphoma) are likely to be secondarily infected and inflamed therefore care is required in interpretation.

ii) Material from cut surface of an excised mass - this is likely to reflect cytology of mass.

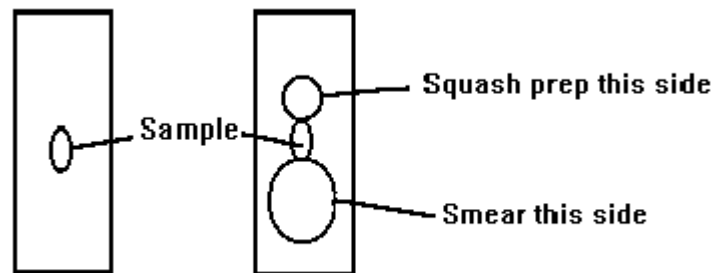
Procedure:

Clean off debris and blood from the surface and touch the mass onto clear microscope slides repetitively and then fix and stain (e.g. Diff Quick).

- **Scrapings:**

Collect material by scraping across the surface of the lesion (before and after cleaning) and placing it onto a microscope slide. Spread the material by a combination of blood smear technique and a squash / slide preparation (Cowell and Tyler 1989).

Combined smear and squash technique:



- **Swabs:**

Collect material from skin or from a discharging sinus lesions. For collection of material from dry skin, moisten the swab in sterile saline and collect sample. Roll the swab along a microscope slide (do not rub).

- **Aspiration biopsies (FNAB):**

Fine needle aspiration biopsy is used for the investigation of solid masses and lymph nodes. Small number of cells are collected which may or may not be truly representative of the pathology present. Use a needle between 19- and 23-gauge and a 10 to 20 ml syringe. The aim of the procedure is to collect material in the needle (not the syringe barrel) and spread onto a microscope slide. The softer the tissue, the smaller the syringe required. Clip the lesion and clean as for venipuncture. Note the biopsy track you use so that it can be removed at surgical excision of mass if required. Introduce the needle tip into the centre of the mass and apply negative pressure by withdrawal of plunger to 3/4 the volume of the barrel. Sample several areas of the mass by redirection of the needle, while maintaining negative pressure, but without allowing the needle tip to leave the mass. With small masses the negative pressure should be relieved whilst redirecting the needle in order to avoid aspiration of surrounding tissue. Remove the needle from the syringe, draw air into the syringe, reconnect to the needle and apply material to slide by rapidly depressing the plunger and spread as described above. Fix, stain and examine the slide.

An Approach to Cytological Examination.

References:

Cowell RL and Tyler RD (1989) Diagnostic cytology of the dog and cat. American Veterinary Publishers, Inc. Goleta, California USA.